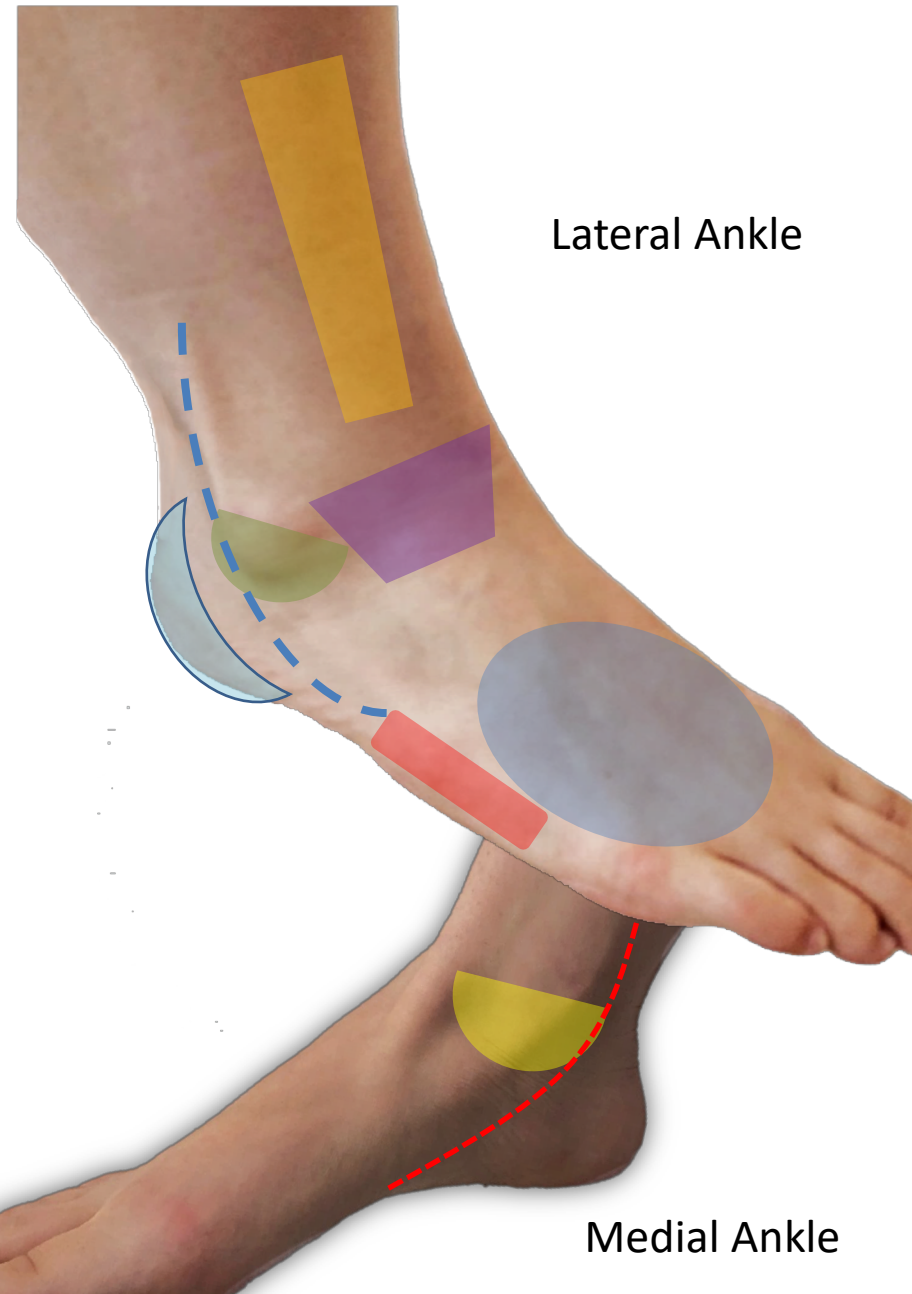


Ankle Pain Diagram



Lateral Ankle

Medial Ankle



Lateral ankle sprain (inversion)
Lateral malleolus fx, ATFL/CFL/PTFL



Medial ankle sprain (eversion)
Medial malleolus fx, deltoid ligament complex



Syndesmosis/Tibiofibular joint
High ankle sprain



5th Metatarsal
Avulsion fracture, Jones fracture
Iselin's apophysitis (base)



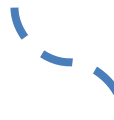Calcaneus
Sever's apophysitis, stress fracture



Anterior Tibiotalar Joint
Talus OCD, anterior impingement



Metatarsals
Traumatic or stress fractures



Peroneal tendons
Peroneal tendinitis, tear



Posterior tibialis
Posterior tibialis tendinitis, tear

Ankle Pain

Reasons to Image

- Acute injury
- Swelling/redness
- + Ottawa criteria
- Catching/locking
- Instability
- Failing conservative care (PT, rest, etc)

Reasons to Refer

- Failing conservative care (PT, rest, etc)
- Swelling
- Catching/locking
- Instability
- Numbness/weakness
- Concerns on imaging

**X-rays views should include:*

AP, Lateral, Mortise